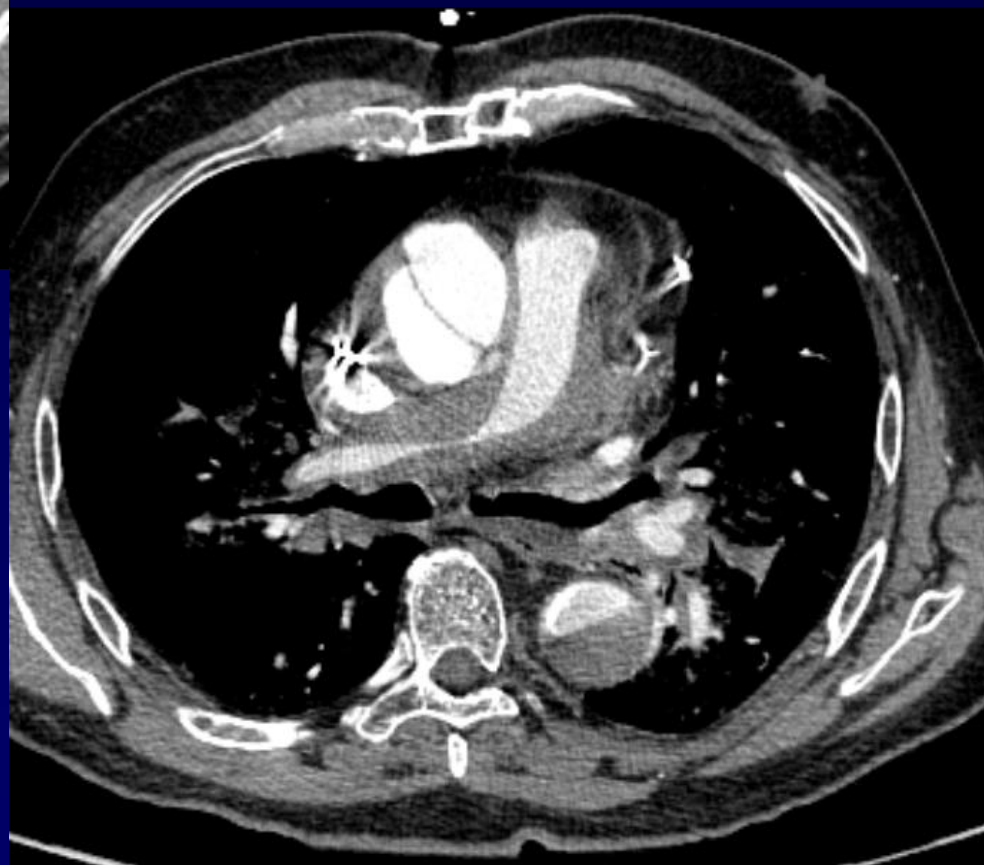
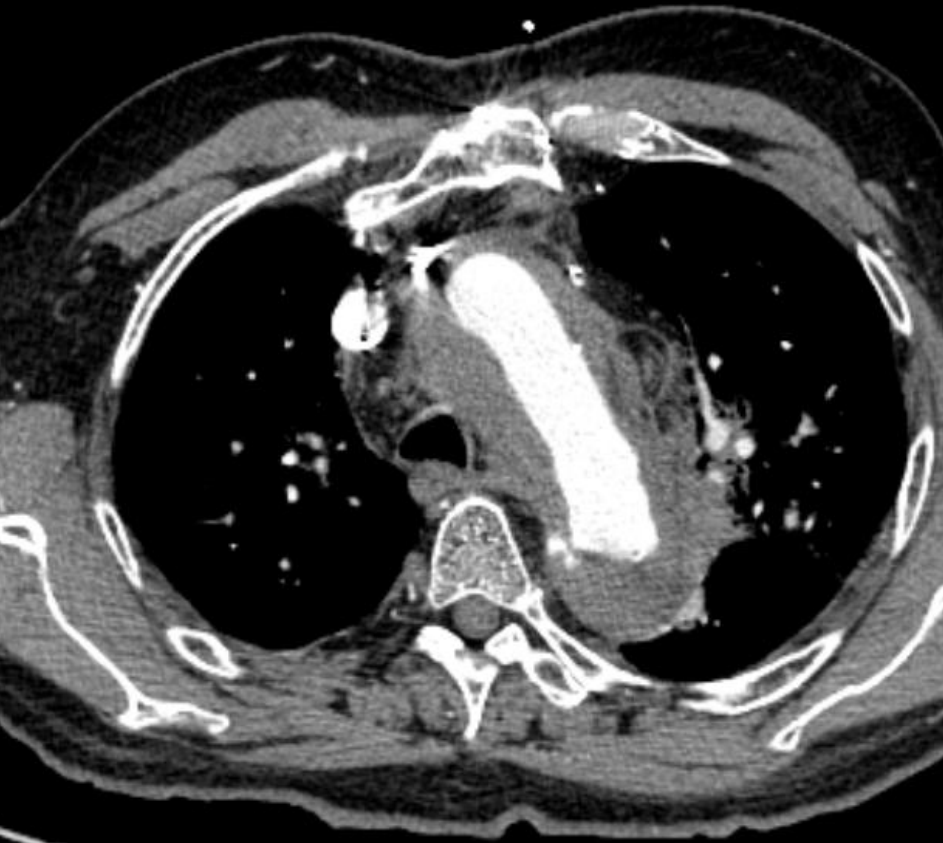

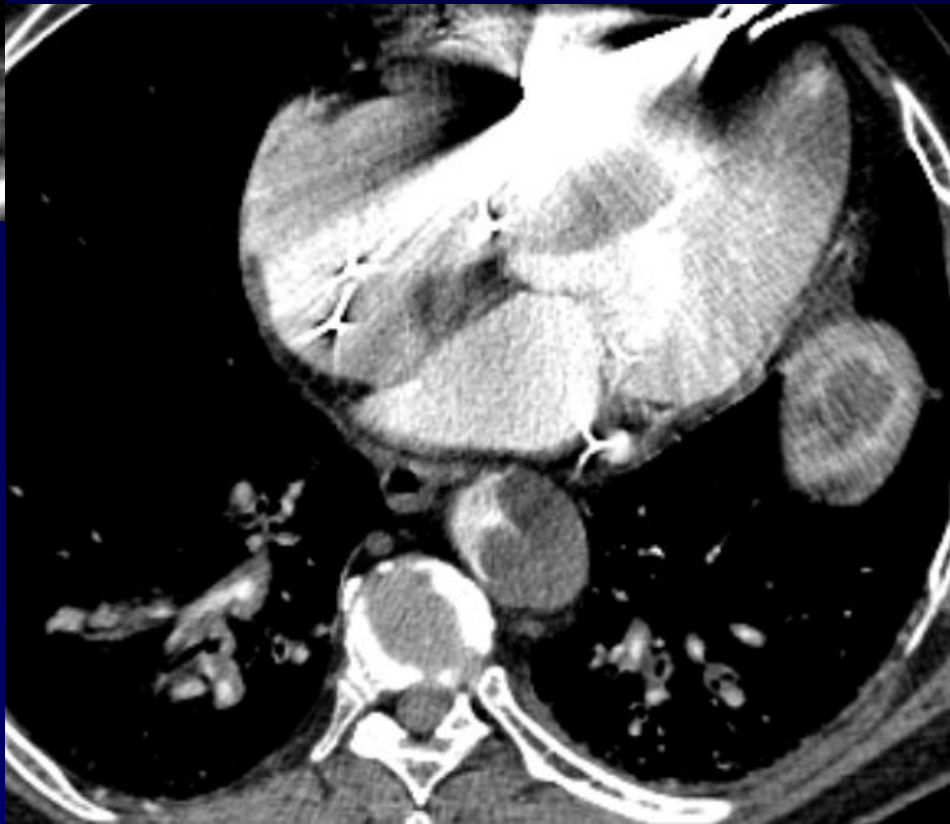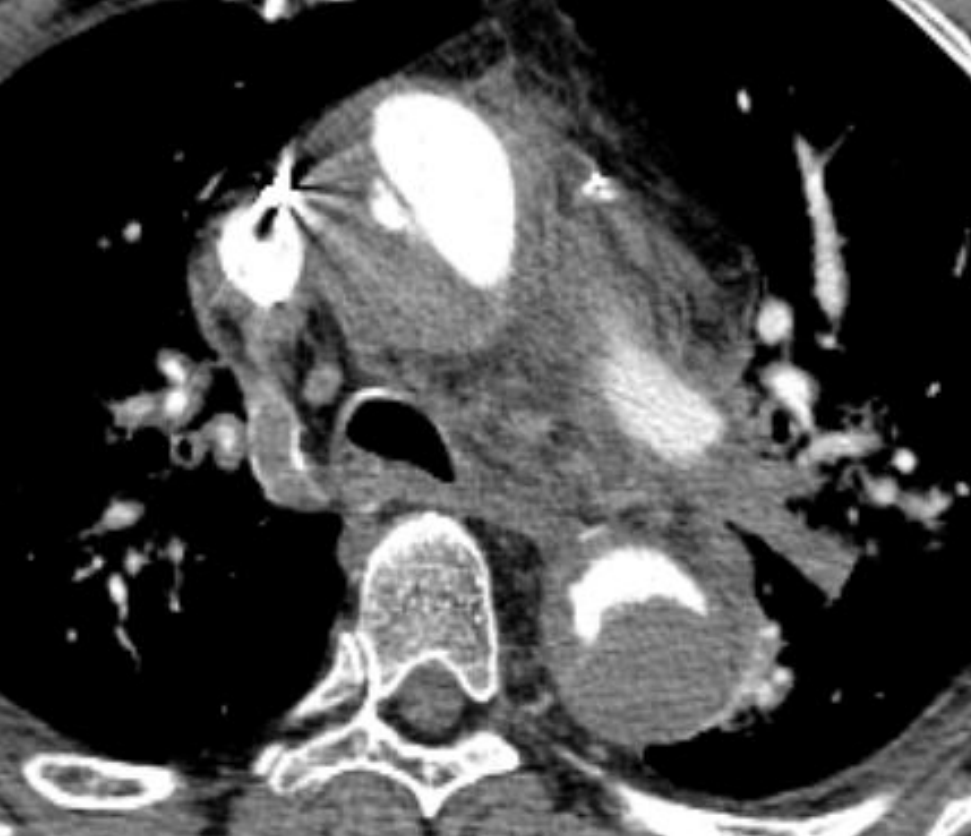


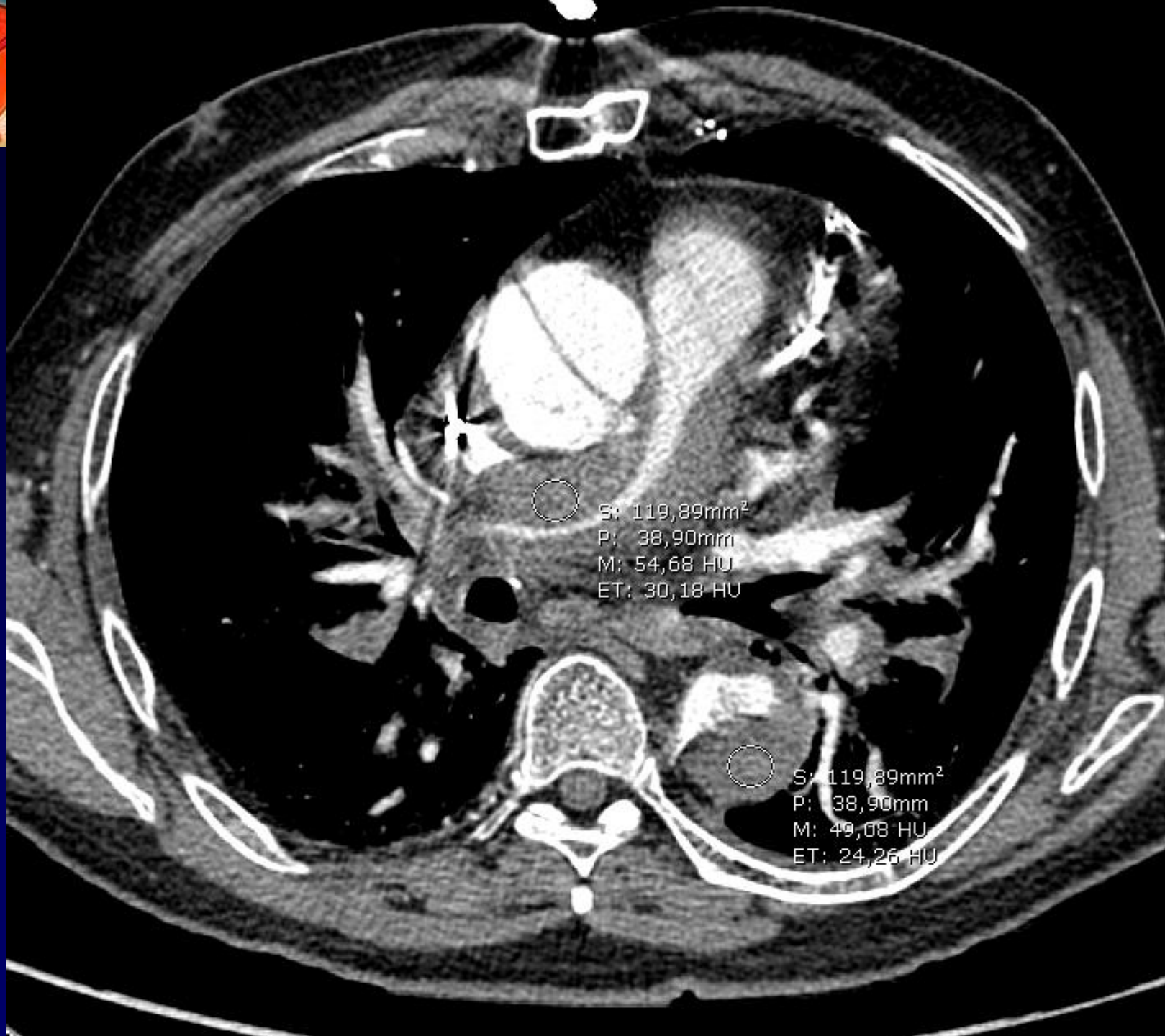Alexis LACOUT

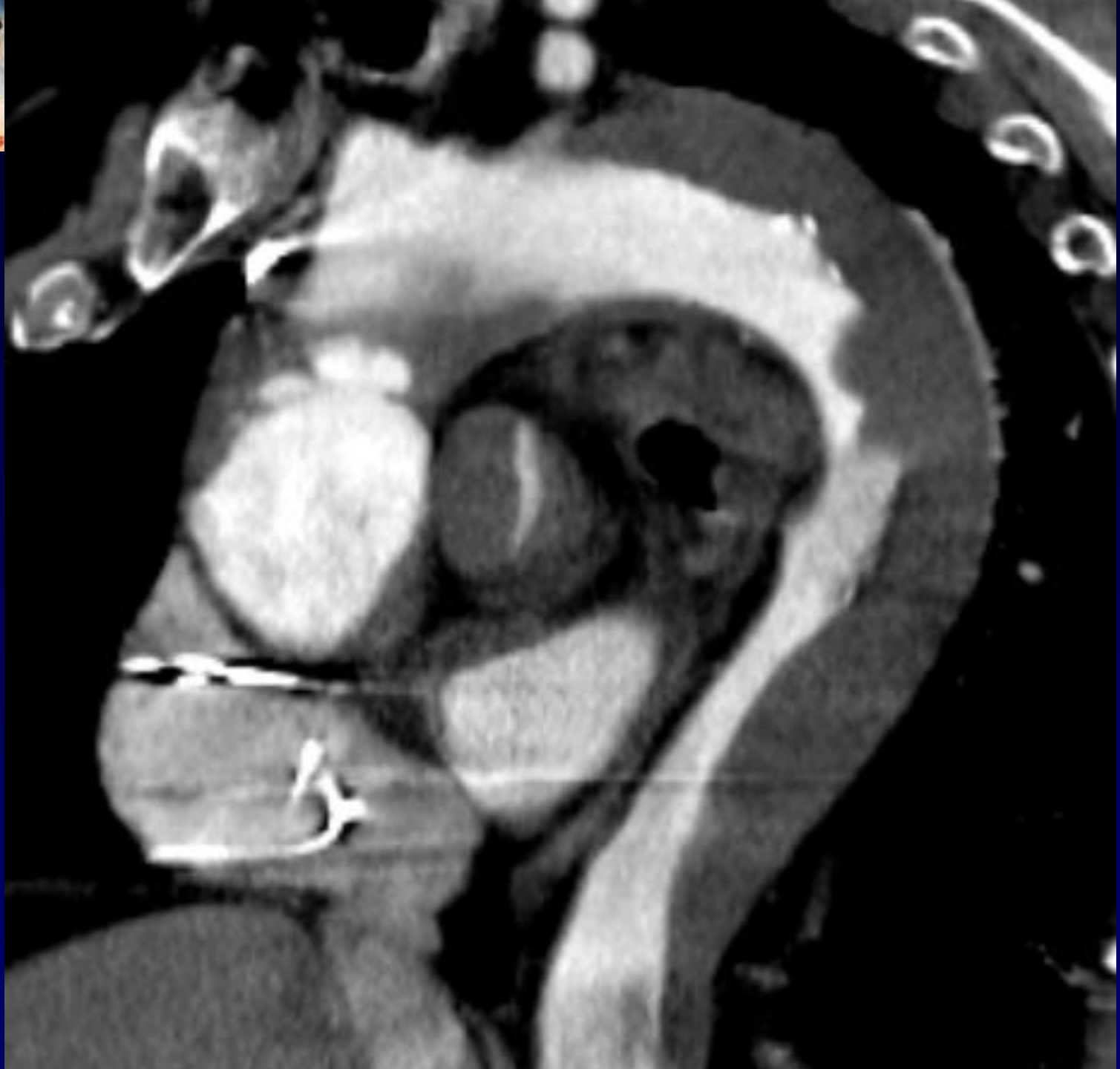Homme de 71 ans

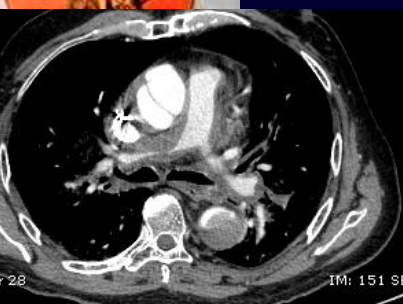
Douleurs thoraciques, dyspnée



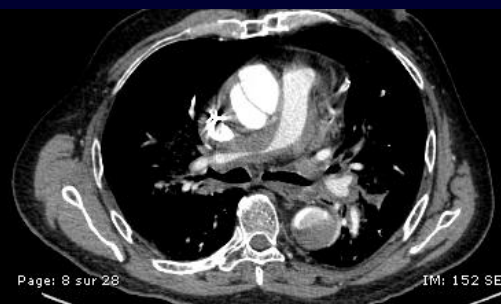



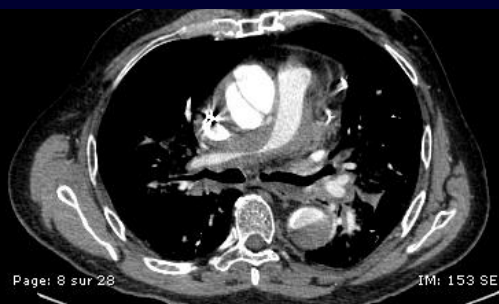




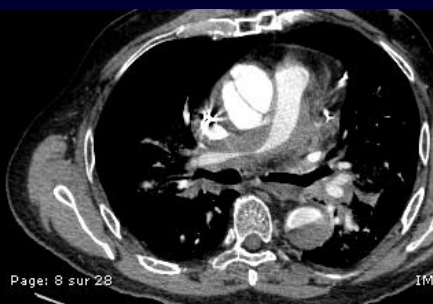IM: 151 SE: 2 Page: 8 sur 28



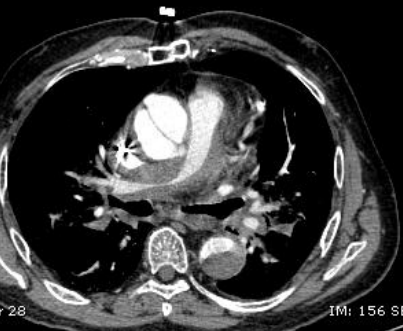
IM: 152 SE: 2 Page: 8 sur 28



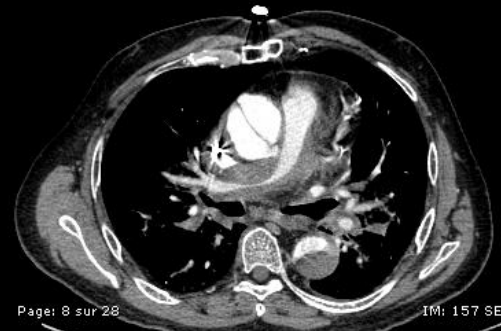IM: 153 SE: 2 Page: 8 sur 28



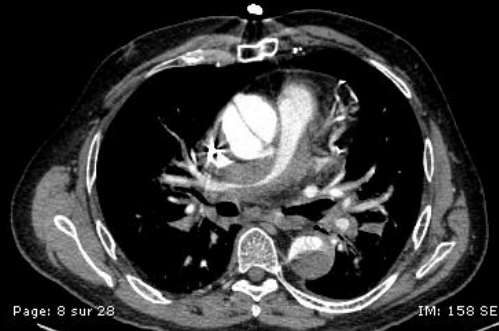
IM: 154 SE: 2 Page: 8 sur 28



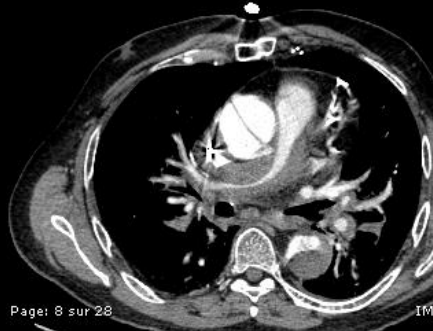
IM: 156 SE: 2 Page: 8 sur 28



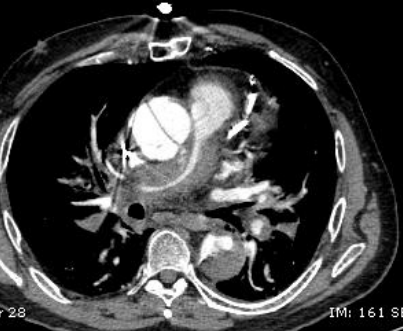
IM: 157 SE: 2 Page: 8 sur 28



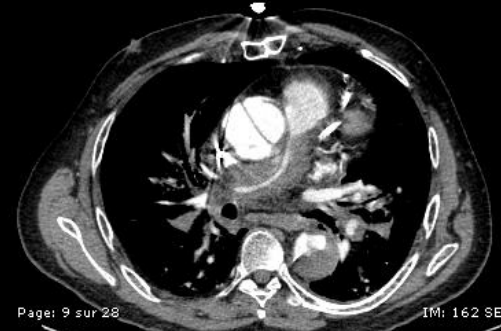
IM: 158 SE: 2 Page: 8 sur 28



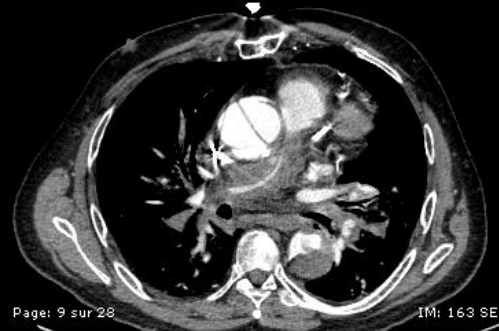
IM: 159 SE: 2 Page: 8 sur 28



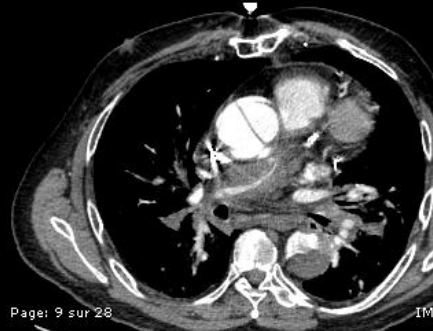
IM: 161 SE: 2 Page: 9 sur 28



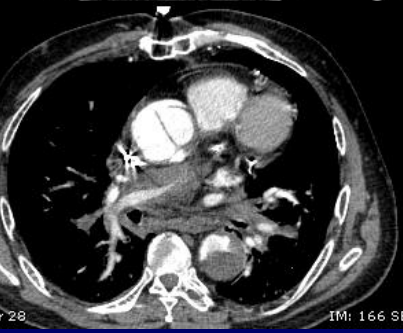
IM: 162 SE: 2 Page: 9 sur 28



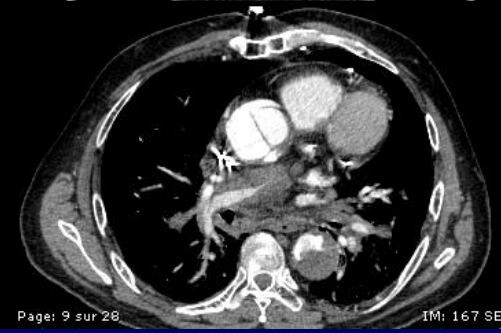
IM: 163 SE: 2 Page: 9 sur 28



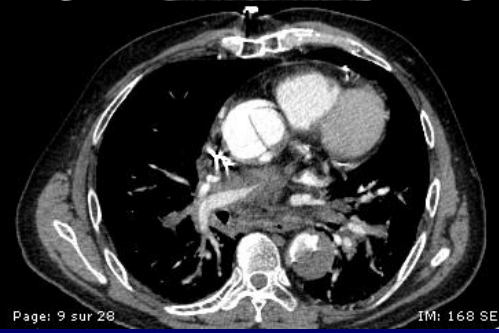
IM: 164 SE: 2 Page: 9 sur 28



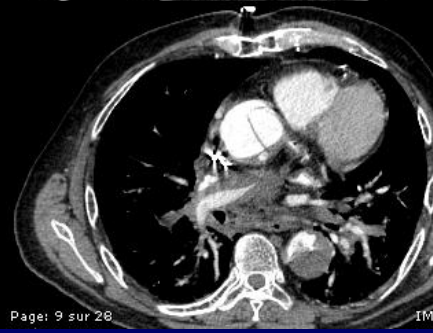
IM: 166 SE: 2 Page: 9 sur 28



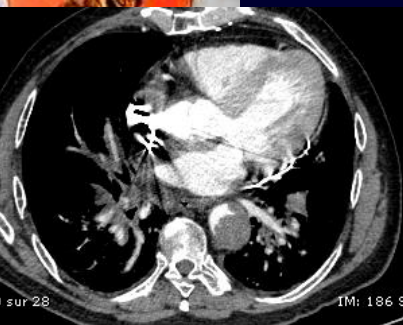
IM: 167 SE: 2 Page: 9 sur 28



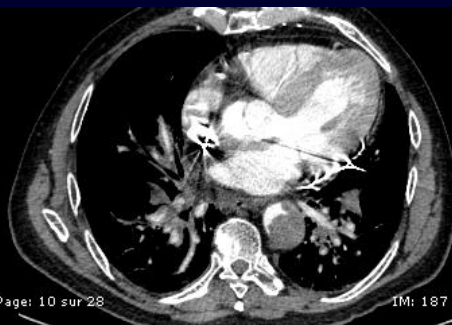
IM: 168 SE: 2 Page: 9 sur 28



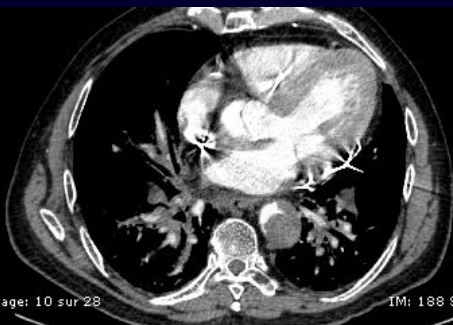
IM: 169 SE: 2 Page: 9 sur 28



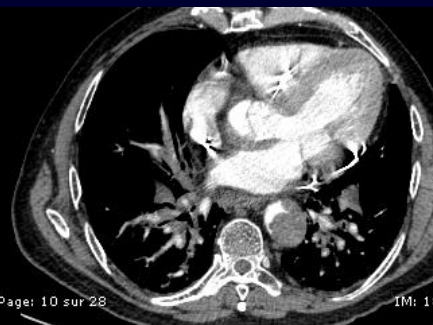
IM: 186 SE: 2 Page: 10 sur 28



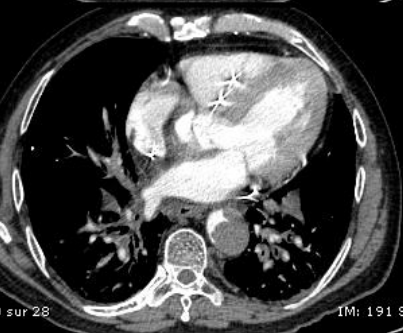
IM: 187 SE: 2 Page: 10 sur 28



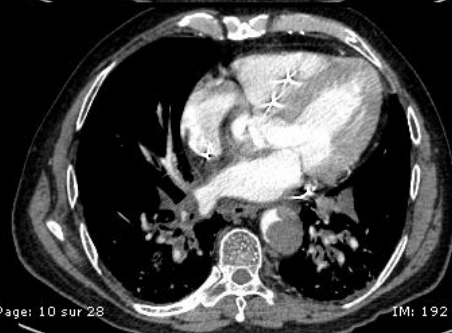
IM: 188 SE: 2 Page: 10 sur 28



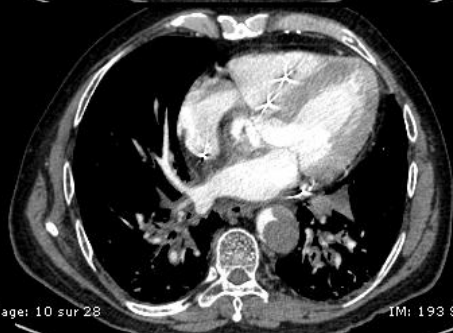
IM: 189 SE: 2 Page: 10 sur 28



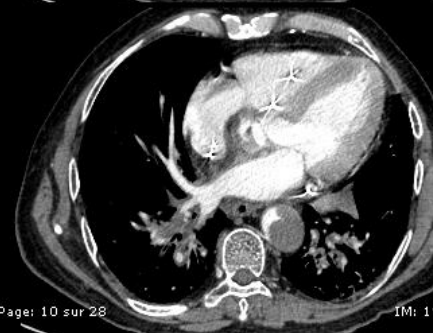
IM: 191 SE: 2 Page: 10 sur 28



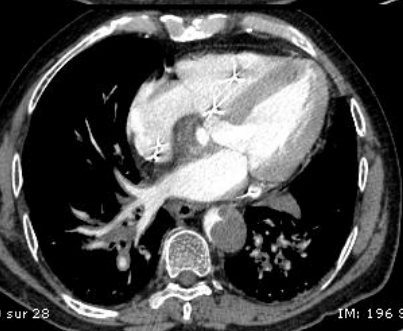
IM: 192 SE: 2 Page: 10 sur 28



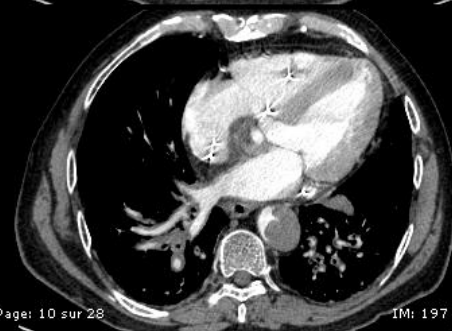
IM: 193 SE: 2 Page: 10 sur 28



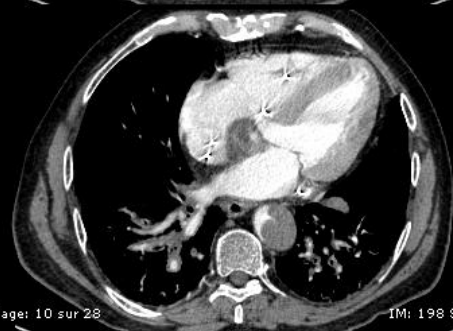
IM: 194 SE: 2 Page: 10 sur 28



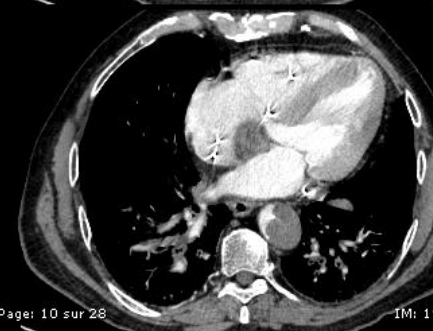
IM: 196 SE: 2 Page: 10 sur 28



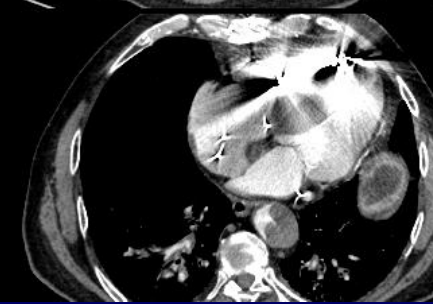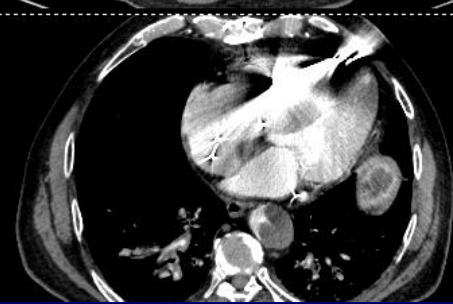
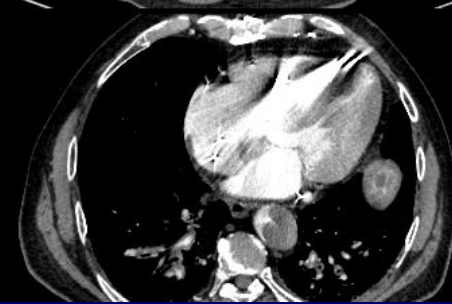
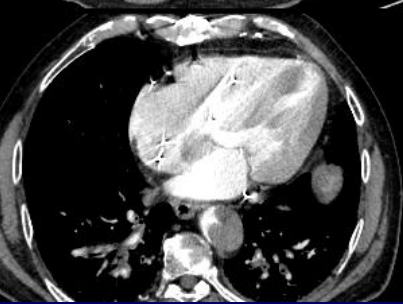
IM: 197 SE: 2 Page: 10 sur 28

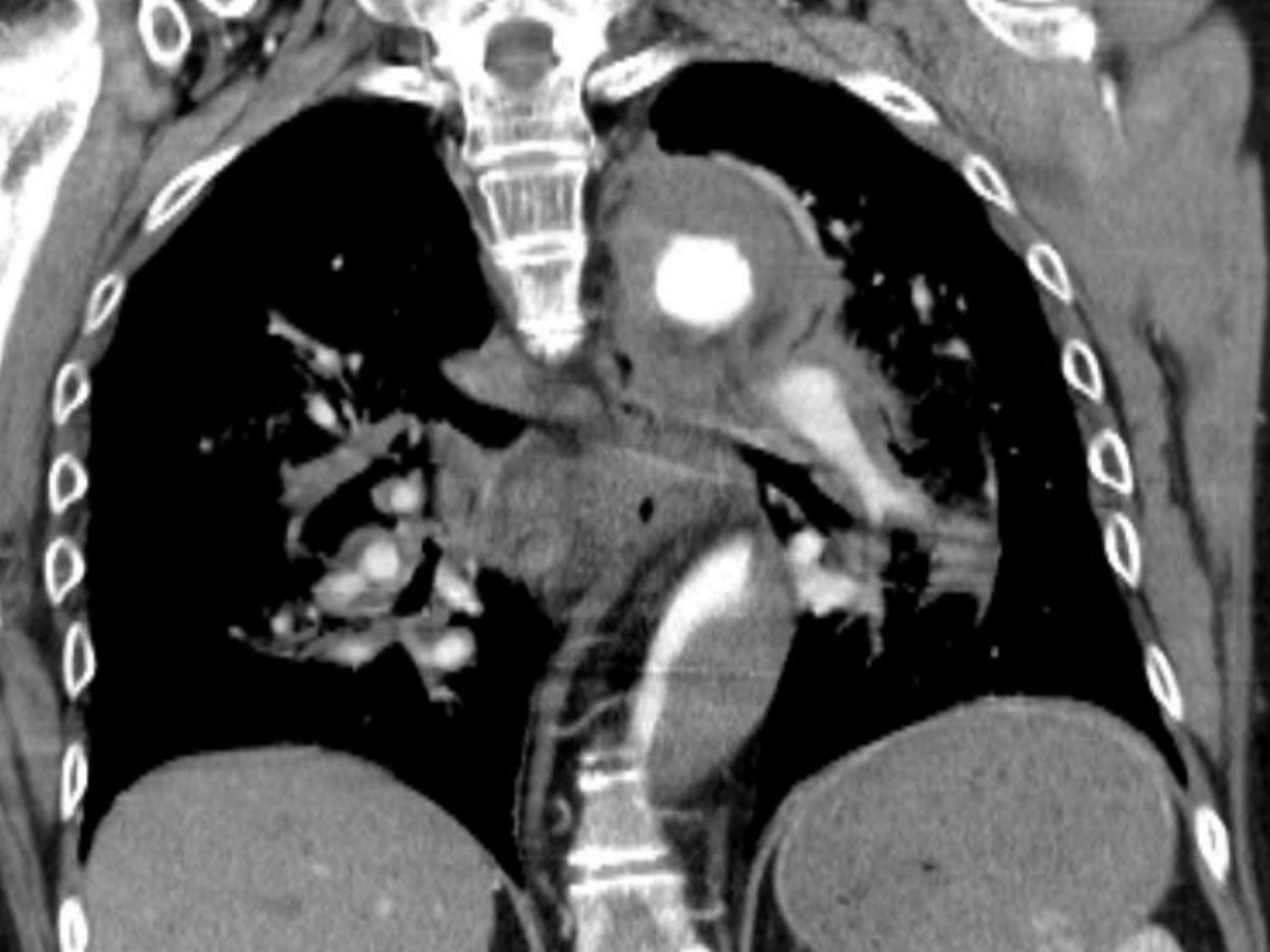

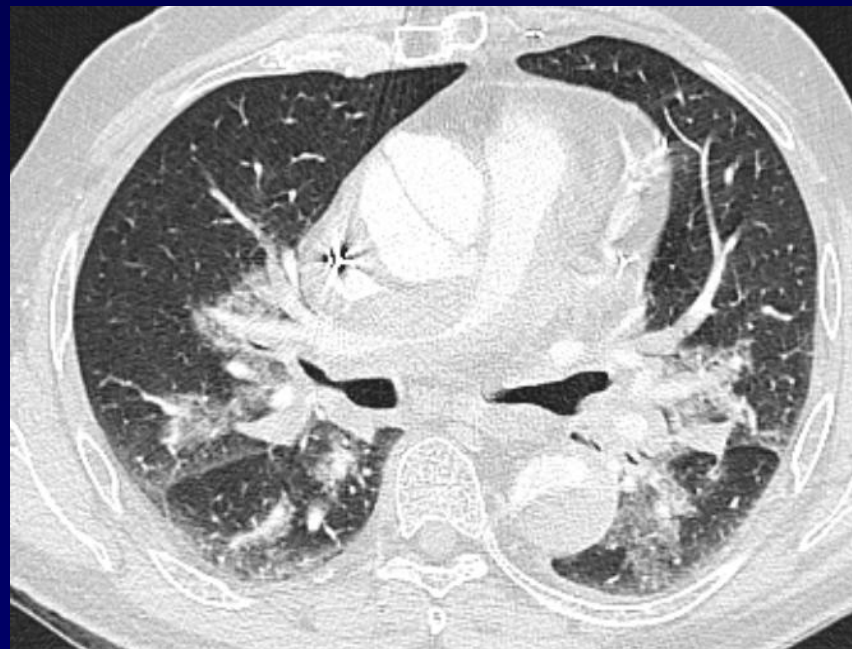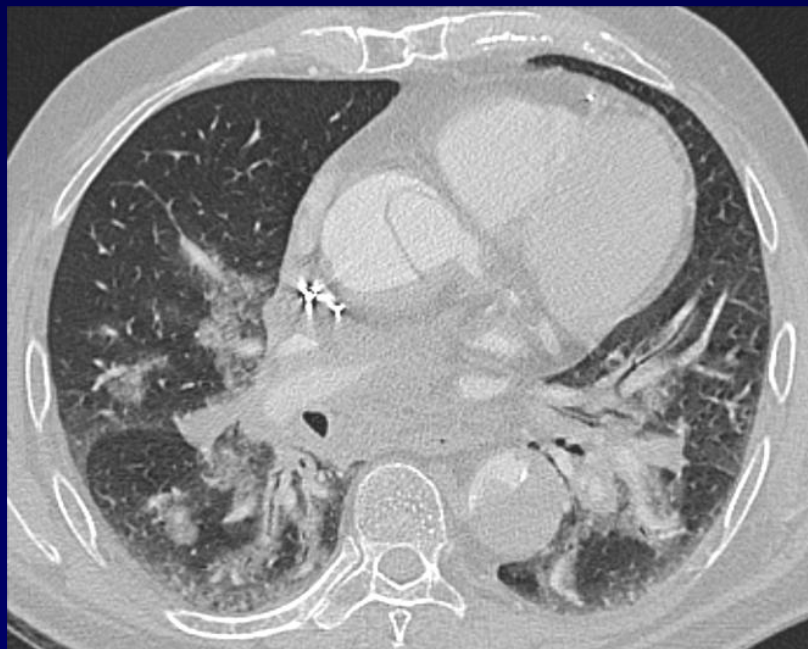
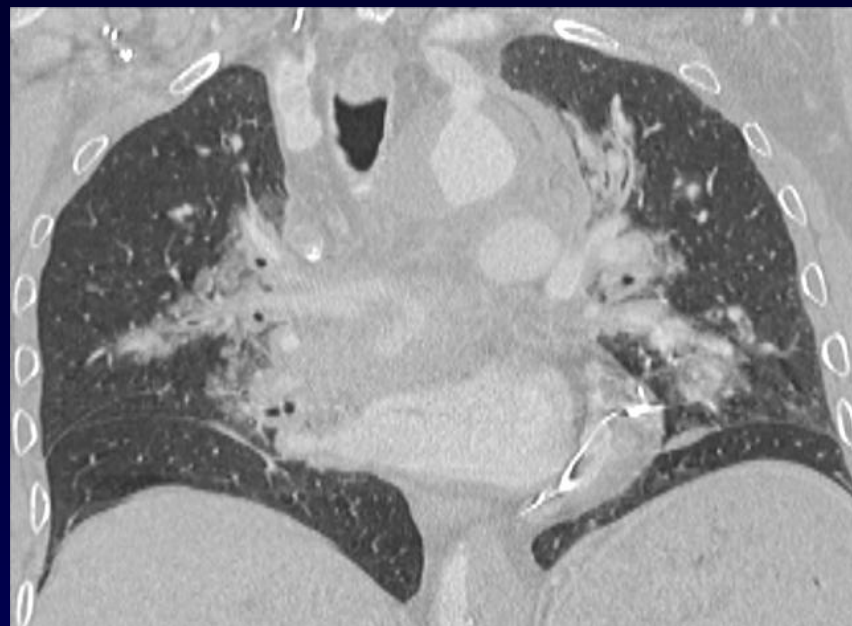
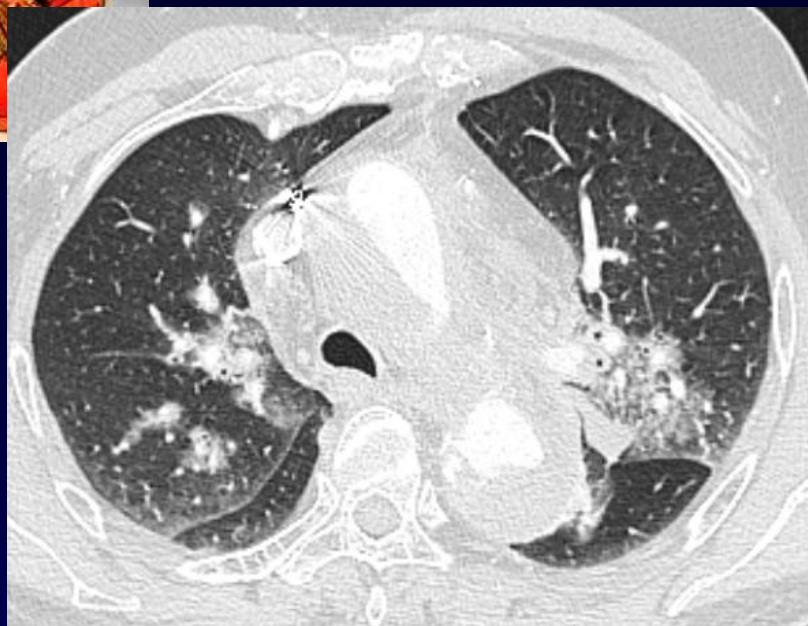IM: 198 SE: 2 Page: 10 sur 28

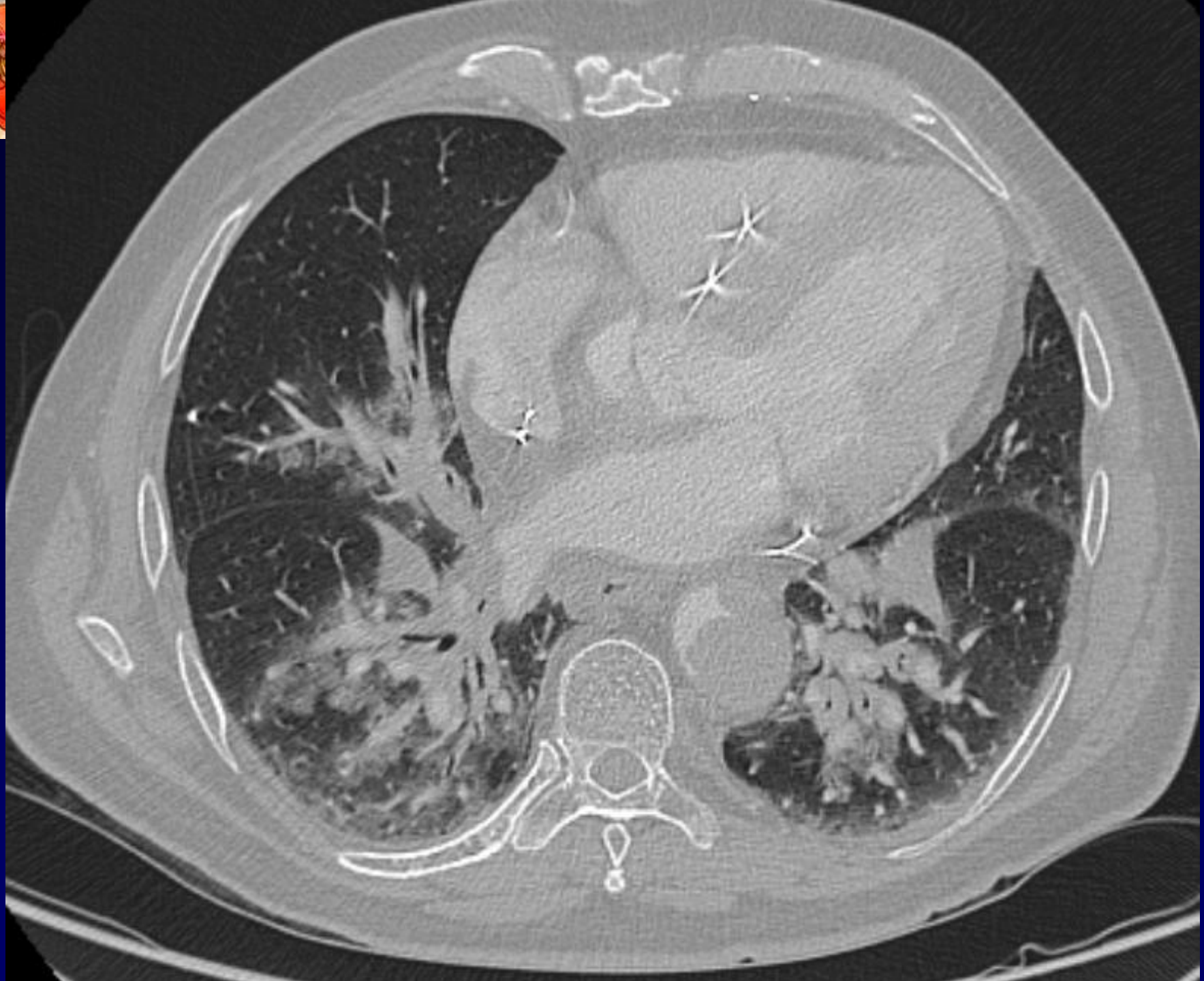


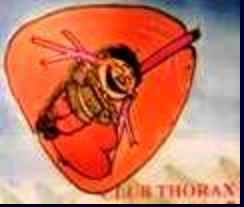
IM: 199 SE: 2 Page: 10 sur 28



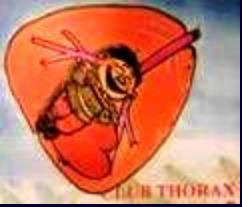







Diagnostic ?



Diagnostic

Dissection aortique de type A de STANFORD

HÉMATOME INTRAMURAL ARTÉRIEL PULMONAIRE ÉTENDU

Sténose artérielle pulmonaire